

What's New in Medicine

abduction finger sign—a new sign to detect unilateral functional paralysis of the upper limb, to differentiate functional from organic paralysis of the arm. Abduction finger movements of one hand are used against resistance with a maximal sustained contraction to detect synkinetic abduction finger movements of the contralateral hand. The abduction finger sign may be a reliable bedside test to discriminate functional from organic arm paralysis.

absent bow tie sign and flipped meniscus sign—may be a sign of central hole tear of discoid meniscus on MRI.

absent halo sign—refers to thyroid ultrasound features associated with malignancy in thyroid nodules. They represent microcalcifications, hypoechogenicity, irregular margins, or are referred to as an *absent halo sign*.

air crescent sign—can be visualized both on radiographs and CT scans of the chest. It is recognized as a crescent-shaped or circumferential area of radiolucency within a parenchymal consolidation or nodular opacity. The air crescent sign can be visualized in a pulmonary cavitory process, which results in air surrounded by radiopaque material along both its inner and outer margins. Despite being described in a number of entities, the air crescent sign is characteristic of invasive pulmonary aspergillosis when seen in the appropriate clinical setting.

antral pad sign—seen on a radiograph of the upper gastrointestinal tract obtained with orally administered contrast material. The sign refers to an extrinsic impression or indentation on the posteroinferior aspect of the antrum. The impres-

sion is generally arcuate and smooth, and it may or may not be associated with an impression on the medial aspect of the duodenum. An impression on the posteroinferior aspect of the gastric antrum is often caused by a mass lesion in the pancreas. However, the gallbladder more commonly causes such as indentation. In any case of this “antral pad sign,” a gallbladder impression should first be excluded.

applause sign—a test of motor control that helps to differentiate progressive supranuclear palsy (PSP) from frontal or striatofrontal degenerative diseases. Patients are asked to clap three times after demonstration by the examiner. A score of 3 is given for 3 claps, a score of 2 for 4 claps, 1 for 5-10 claps, and 0 for greater than 10 claps. The test has been previously reported to be indicative of various neurodegenerative disorders. It is highly specific for parkinsonian disorders but it is not a specific sign for PSP; it appears to be most sensitive for corticobasal degeneration.

atlantoaxial rotatory subluxation (ARS, AARS).

atomizer sign—primarily seen overlying the Adam's apple both in women and girls and called the *atomizer sign*. Example: allergic contact dermatitis to fragrances.

Bernese periacetabular osteotomy.

best-corrected visual acuity (BCVA).

binary sign in Anderson-Fabry cardiomyopathy.

bird's beak sign—(1) Thoracic endovascular stent graft with a bird's beak sign. (2) Barium enema revealed a “bird beak sign” at the splenic flexure, which confirmed the diagnosis of splenic flexure

colonic volvulus. (3) In 28 fasting patients with achalasia, sonography showed dilatation, retention of fluid, and smooth narrowing of the distal esophagus (like a bird's beak).

bright facet sign—on fast spin echo T2-weighted magnetic resonance imaging, the presence of high signal within the facet articulations, indicating degenerative facet and disk changes.

Cervista™ HPV HR extraction kit—used to identify human papillomavirus (HPV) DNA from 14 high-risk genital HPV types that are commonly associated with cervical cancer. If test results are positive, the patient is likely to be infected with HPV.

chronic inflammatory demyelinating polyneuropathy (CIDP).

coffee bean sign—used to refer to a proximal distended colon at the left upper quadrant. Related to splenic flexure volvulus.

colon single-stripe sign—chronic longitudinal NSAID-related ulcer of the colon or longitudinal ulcer in ischemic colitis.

comet sign—(1) the appearance of an adjacent eccentric, tapering soft-tissue mass corresponding to the noncalcified portion of a pelvic vein (phlebolith) on unenhanced helical CT which can help differentiate calculi from phlebolith; (2) on sonogram, the appearance of echoes around microliths in the parotid gland; (3) a clinical sign of unusual pruritic dermatitis caused by *Pyemotes ventricosus*, a parasite of the furniture beetle *Anobium punctatum*.

crack (and stack) method (Oph)—a highly adaptable cataract surgical procedure that allows the surgeon to perform phacoemulsification

See other new, difficult, and hard-to-find medical terms in the electronic 11th edition of *Vera Pyle's Current Medical Terminology* published by Health Professions Institute, 2007.

Update

with the nucleus cracked into 4 quadrants.

DARC (detection of apoptosing retinal cells)—a noninvasive real-time imaging technology.

delamination cysts—a previously unrecognized and novel radiographic sign that can preoperatively identify acetabular cartilage delamination in patients with labral tears, thereby facilitating the selection of the appropriate surgery and determining prognosis.

drop (or dropped) toe sign—resting posture of the toes in plantarflexion and absent active dorsiflexion movement after plantar stimulation of the foot. Considered an indicator of neurologic impairment in congenital clubfoot.

duodenal wind sock sign—an intraluminal duodenal diverticulum seen on an upper GI series. This sign consists of a barium-filled sac that lies entirely within the duodenum and that is surrounded by a narrow radiolucent line that is well demonstrated as the barium in the duodenum passes distal to the diverticulum. Because of the thin radiolucent stripe surrounding the diverticulum, the appearance on an upper GI series has also been described as a *halo sign*.

dural tail sign—seen on contrast material-enhanced magnetic resonance images as a thickening of the enhanced dura mater that resembles a tail extending from a mass. Dural tail typically associated with meningioma is less than complete. Both tumor invasion and hypervascular reaction may be responsible for the dural tail sign.

eye-of-the-tiger sign—most commonly described in Hallervorden-Spatz syndrome, where the ring of marked hypointensity involving the globus pallidus on T2-weighted MR images is due to excess iron accumulation.

eye sign—as seen in an acute stroke. It's not necessarily a poor outcome.

face of the giant panda sign—on T2-weighted MRI of the midbrain. Focal accumulation of gallium ⁶⁷citrate in the nasopharynx, parotid gland, and lacrimal gland produces a distinctive pattern, the panda sign, that is strikingly similar to the dark markings of the giant panda. Also, *double panda sign* in Wilson disease. See also *panda sign*.

Fahr syndrome—a rare, genetically dominant, inherited neurological disorder characterized by abnormal deposits of calcium in areas of the brain that control movement, including the basal ganglia and the cerebral cortex.

FAST (focused assessment by sonography in trauma)—a focused exam using ultrasound to diagnose hemorrhage in a trauma setting, takes about 3 minutes, and uses 4 primary views: the RUQ, LUQ, subphoid, and suprapubic.

FC2 female condom—a sheath with one open end. There is an outer ring at the open end, and, although not attached to the condom, there is an inner ring inside the sheath that aids in insertion. The FC2 female condom is inserted into the vagina before intercourse, and it is a barrier to sperm between the penis and the vagina. It reduces access of semen to the vagina, and thereby prevents or decreases the rate of pregnancy compared to unprotected intercourse. Also, the condom barrier prevents access to the vagina of pathogenic bacteria and viruses in secretions as well as contact between lesions on the shaft of the penis and the vagina.

floating fat-density debris sign—a well-defined mass mottled with gas bubbles associated with an encapsulating wall, as seen on CT scan. The floating fat-density

debris sign and a lesion in the stomach that appears similar to the obstructing mass is typical of a small-bowel bezoar. An isolated amorphous mass mottled with gas bubbles is typical of small-bowel feces.

floating thrombus sign—pulmonary thromboembolism with thrombus trapped in a patent foramen ovale on CT pulmonary angiogram.

football sign—massive pneumoperitoneum in an infant.

four-quadrant cracking method (Oph)—see *crack method*.

galloping colored horse sign—M-mode Doppler pattern of severe functional mitral regurgitation in the presence of high left ventricular filling pressures.

Genfind™ DNA extraction kit—used to identify human papillomavirus (HPV) DNA from 14 high-risk genital HPV types that are commonly associated with cervical cancer. If test results are positive, the patient is likely to be infected with HPV.

grating sign in bladder calculi.

head supporting sign during reclining—may be the sole neurological finding in some patients with involvement of the craniovertebral junction. The craniovertebral (CV) junction can be involved in many diseases, e.g., rheumatoid arthritis, as well as destructive bone pathologies such as tumor and tuberculosis (craniovertebral Pott's disease).

hot cross bun sign—a radiological sign which is highly specific for multiple system atrophy. It is also seen in parkinsonism secondary to vasculitis, and in variant Creutzfeldt-Jakob disease.

intermetatarsal fat pad sign—radiographic aid to diagnosis of occult tarsometatarsal joint injuries.

intestinal juice—a fluid that is secreted in small quantity in the

Update

small intestine, is highly variable in constitution, and contains especially various enzymes (as erepsin, lipase, lactase, enterokinase, and amylase) and mucus. Also called *succus entericus*.

inverted V sign—in subacute combined degeneration of spinal cord.

knife-cut sign—linear erosive herpes simplex virus infection in immunocompromised patients. Herpes simplex virus presents as intertriginous fissures similar to the “knife-cut” ulcers associated with metastatic Crohn’s disease. Intertriginous fissures due to herpes simplex virus are recognizable patterns of viral infections in immunocompromised hosts.

LifeStent FlexStar and FlexStar XL vascular stent systems—used to re-open stenotic (narrowed) regions of the superficial femoral and proximal popliteal arteries which supply blood to the legs.

Luck’s histologic stages (zones)—proliferative phase, involutinal phase, and residual phase.

Medtronic Attain Ability lead—a surgically implanted insulated wire that is designed to be used as part of a biventricular pacemaker system.

Medtronic Ensemble transcatheter valve delivery system—a catheter that helps guide the Melody transcatheter pulmonary valve into the heart. See *Medtronic Melody*.

Medtronic Melody transcatheter pulmonary valve—a manufactured replacement pulmonary heart valve that had already been previously repaired. The Melody valve is made from a cow’s jugular vein valve that is sewn into a small metal stent (scaffolding). See *Medtronic Ensemble*.

Medtronic METRx microdissection system—a unique muscle-splitting approach that allows

surgeons to access the spine with a posterior approach without cutting or removing muscle from the spine. With this minimally invasive approach, surgeons are able to precisely locate, see and remove herniated disks in the spine through tunnels created by tubes that split back muscle, much like a sewing needle splits the weave of fabric, along natural divisions. No muscle fiber is cut, only separated.

modified osteo-odonto-keratoprostheses (MOOKP)—a sight-restoring procedure. Usage: “For certain patients whose bodies reject a transplanted or artificial cornea, this procedure ‘of last resort’ implants the patient’s tooth in the eye to anchor a prosthetic lens and restore vision.”

Morgellons disease and the tweezer sign—a dermatologic or psychiatric delusion of parasitosis. See *tweezer sign*.

muscle retracting sign—an index of the discontinuation of endoscopic submucosal dissection, but it is impossible to diagnose preoperatively.

Navistar ThermoCool irrigated deflectable diagnostic/ablation catheter—used to destroy (ablate) abnormal heart tissue that causes an intermittent abnormal heartbeat in the upper chambers of the heart (paroxysmal atrial fibrillation).

Neuro Patties—sponges that offer exceptional pliability, compliance, and a singular design not found in existing neurosurgical absorbable materials.

nonlifting sign and forceps biopsy—widely used for evaluating the invasion depth of colorectal tumors. It is commonly accepted that endoscopic mucosal resection is contraindicated for colorectal tumors with a nonlifting sign because of the probability of massive submucosal invasion.

NovaSure procedure—a one-time endometrial ablation treatment. This minimally invasive procedure controls heavy bleeding by using energy to remove the lining of the uterus. The average treatment time is about 90 seconds and needs to be performed only once to lighten or stop heavy menstrual periods.

ocular tilt reaction—a clinical sign of cerebellar infarctions.

ominous sign—radiologic findings that consist of root-type peri-anchor radiolucency located below the equator of the glenoid. Osteophytes of the humeral head together with the ominous sign is considered progression of anchor arthropathy and may suggest early surgical intervention.

open-ring imaging sign—often present in large, contrast-enhancing demyelinating lesions and helps to differentiate them from neoplasms and infections. On cerebral angiography, tumor-like masses of demyelination may occupy an intermediate position between acute multiple sclerosis and post-infectious encephalitis.

ovarian crescent sign—used in the evaluation of adnexal masses as an sonographic marker for malignancy.

ovarian vascular pedicle sign—a way of differentiating ovarian from subserosal uterine lesions on single-detector helical CT. The presence of the ovarian vascular pedicle sign on helical CT is valuable for confirming the ovarian origin of a pelvic tumor and for differentiating an ovarian tumor from subserosal uterine myoma.

panda sign—avid and symmetrical radiogallium accumulation in the lacrimal and parotid glands on gallium scintigraphy in a patient with cutaneous manifestations of systemic sarcoidosis. See also *face of the giant panda sign*.

Update

ProGEL pleural air leak sealant—a surgical sealant made of human serum albumin and a polyethylene glycol (PEG) crosslinker that forms a clear flexible gel on mixing. Surgeons use the device to seal air leaks on lung tissue after standard closure techniques (that is, sutures or staples) for open resection of lung tissue.

ProTack fixation device—a sterile, single use device for fixation of prosthetic material, such as hernia mesh, to soft tissue. The tack is helical and made of titanium. The overall length of the shaft is approximately 35.5 cm. ProTack comes in a 30 tack configuration.

pseudointercondylar notch sign—manifestation of osteochondritis dissecans of the trochlea; mimicking an intercondylar notch.

Reclaim deep brain stimulation—a totally implanted brain stimulator intended to suppress symptoms associated with obsessive compulsive disorder (OCD) that are not adequately controlled with medications and/or other therapies.

reversal sign (Radiol)—Usage: “Total-body radiographs and non-enhanced CT of the brain showed fracture of the right clavicle, pericerebral hemorrhage, and brain damage with reversal sign.”

reverse and pseudoreverse cortical sign in thoracolumbar burst fracture—sagittal reconstruction in axial CT. What appears to be a flipped piece of posterior vertebral body is actually part of the superior or inferior endplate that is depressed into the comminuted vertebral body.

rolled-up tongue sign—a sign of previous caustic injury.

sagittal sign—direction of the genital tubercle. Downward direction of the genital tubercle indicates a female fetus, and upward direction

a male fetus on ultrasonography in late first and early second trimester to determine sex of fetus.

Saphris (asenapine)—an oral antipsychotic medication that is administered sublingually twice daily. It is used for treatment of acute schizophrenia in adults and also for acute episodes of mania in bipolar 1 disorder.

sentinel clot sign—an important clue for locating the bleeding source when other localizing findings of vessel injury are not present.

sequential compression stockings (socks)—plastic leg wraps that help prevent blood clots by inflating and deflating around the legs. The compression is delivered in a sequential manner up the leg, producing a wavelike milking effect to evacuate leg veins. Sequential devices have been proven to be more effective than single-chamber, evenly distributed pressure in preventing DVTs. The compression is set to cycle regularly (for example, every 60 seconds). Devices are available for feet, calves, and/or thighs.

sign of the fox—the typical appearance of the wounds just prior to closure after bilateral subinguinal microsurgical varicocelectomy.

sliding lung sign—a sonographic sign which appears to hold promise in certain emergency situations including diagnosis of a pneumothorax and confirmation of endotracheal tube placement.

Sluder syndrome—sphenopalatine neuralgia.

succus entericus—intestinal juice referring to the clear to pale yellow watery secretions from the glands lining the small intestine walls. See *intestinal juice*.

Synvisc-One—a single viscosupplementation injection directly into the intra-articular space inside the knee. Indicated for the treatment of pain of the knee in patients who

have failed to respond adequately to conservative non-pharmacologic therapy and simple analgesics, e.g., acetaminophen.

TECNIS multifocal foldable intraocular lens—a plastic lens used to restore vision and replace the natural lens of the eye after it is removed during cataract surgery.

traumatic atlantoaxial rotatory dislocation (TAARD).

tubal ring sign—a ring-enhancing cystic structure in the adnexa corresponding to tubal ring sign of ectopic pregnancy seen on pelvic ultrasound.

tweezer sign—the practice of dermatology patients who frequently dig at their lesions with household items such as nail clippers or tweezers as well as their own nails. The use of mechanical instruments in addition to fingernails may signify a more malignant psychological profile. See *Margellons disease*.

VersaStep trocar (not Verres-type trocar) (used in donor kidney surgery)—bladeless trocar.

WallFlex biliary RX fully covered stent—indicated for the palliative treatment of biliary strictures produced by malignant neoplasms. The WallFlex biliary RX stent is constructed of braided, platinum-cored Nitinol wire (Platinol wire) and features three key components: radial force to help maintain duct patency and resist migration, flexibility to aid in conforming to tortuous anatomies and full-length radiopacity to enhance stent visibility under fluoroscopy.

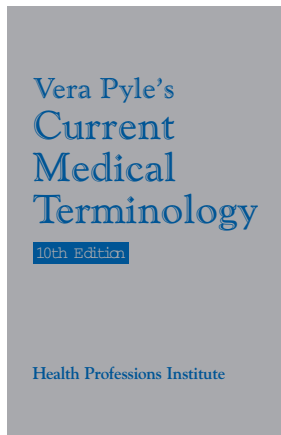
XACT foldable hydrophobic acrylic UV light-absorbing posterior chamber IOL—a plastic lens used to replace the natural lens after it is removed during cataract surgery to restore vision.

Vera Pyle's Current Medical Terminology, 11th ed.

****Electronic****

Transcriptionists have had “Vera’s silver book” on their desk for decades.

Now you can put it on your computer!



SMASH (simultaneous acquisition of spatial harmonics) method—used in MRI procedures.

anvil dunk—a procedure used in laparoscopically performed gastric bypass to construct a gastrojejunostomy. The head of a stapling anvil is used to invaginate the stomach wall in order to bring the surgically created openings in the stomach and jejunum into apposition and stabilize them while they are being sutured together. See also *dunked end-to-end anastomosis*.

bird-beak sign (Radiol)—abrupt, smooth tapering of the distal esophagus on barium swallow, an indication of achalasia.

black knee prosthesis—a femoral component consisting of zirconium metal that has been heated and cooled in oxygen. This oxidizes the surface 5 microns of the metal and turns it into a black ceramic finish.

capillary isotachopheresis (cITP)—a modification of electrophoresis in which the use of two electrolytes with different chemical properties permits more rapid and more complete separation of analytes. It is a more sensitive means of measuring LDL subfractions in plasma.

8-to-S-plasty—a modified technique for closing a skin defect shaped like an 8 (two adjoining round lesions). The traditional method of repair by creating a single elliptical defect sacrifices healthy skin. In the Burow 8-to-S plasty, one triangle of skin with its apex at the constriction in the figure 8 is advanced to close one of the circular defects, and the other triangle of skin is advanced to close the other. No incisions are required and no skin is sacrificed. The suture line after closing resembles an “S”.

odd facet of the patella—the 7th facet of the articular surface of the patella, being the most medial portion. Only at 135 degrees of flexion does the odd facet contact the medial femoral condyles. Therefore, in most patients, it is a very underused part of the articular surface. Underuse has been incriminated as a cause of damage to the articular surface, an example being chondromalacia.

rendezvous laparoendoscopic technique—a technique used in endoscopic sphincterotomy to facilitate the identification and cannulation of the papilla. Using this technique, a guidewire is inserted through the cystic duct, caught with an endoscopic polypectomy loop, extracted from the operative channel and cannulized with a sphincterotome. This is then pulled through the papilla in the common bile duct, thus completing the

This 11th edition of
Vera Pyle's Current Medical Terminology
is available **only** in electronic format!

Features of electronic version:

- Glossary format: Definitions, explanations, and examples of usage in dictation.
- New, difficult, and “odd-ball” terms that are hard to find or verify.
- More phonetic entries than ever.
- Researched and compiled *by* transcriptionists *for* transcriptionists.
- Numerous bookmarks and major category headings make browsing easier.
- Convenient search capability instantly takes you to all uses of your word.

System Requirements:

- Windows 2000, 2003, XP, or Vista
- LockLizard Safeguard PDF Viewer (free)

*“Vera on my computer?
I’m in heaven!”*

Not sure Vera will work on your system?

Contact our tech support department to see if we can help.
E-mail: hpi@hpisum.com Phone: 209-551-2112 x 216.



Health Professions Institute

www.hpisum.com